

# Understanding bone safety zones during bone marrow aspiration from the iliac crest: the sector rule

Jacques Hernigou · Laure Picard · Alexandra Alves ·  
Jonathan Silvera · Yasuhiro Homma · Philippe Hernigou

Received: 23 March 2014 / Accepted: 25 March 2014 / Published online: 3 May 2014  
© Springer-Verlag Berlin Heidelberg 2014

## Abstract

**Purpose** Should the trocar suddenly lose contact with bone during bone marrow aspiration, it may result in visceral injury. The anatomy of the ilium and the structures adjacent to the iliac bone were studied to determine the danger of breach by a trocar introduced into the iliac crest.

**Methods** The authors followed two series of patients, one series to do measurements of distance and angles of the structures at risk to the iliac bone and the other to evaluate the risk of a trocar being directed outside the iliac wing during bone marrow aspiration. The authors also examined 24 pelvises by computed tomography (CT) scans of mature adults (48 iliac crests). Lines dividing the iliac wing into six equal sectors were used to form sectors (e.g. sector 1 anterior, sector 6 posterior). Vascular or neurological structures were considered at risk if they were accessible to the tip of a 10-cm trocar introduced into the iliac crest with a possible deviation of 20° from the plane of the iliac wing on the three-dimensional reconstruction. The authors tracked bone marrow aspiration of six different surgeons and calculated among 120 patients (480 entry points) the number of times the needle lost contact with bone in each sector of aspiration.

**Results** The sector system reliably predicted safe and unsafe areas for trocar placement. Among the 480 entry points in the 120 patients, 94 breaches were observed and higher risks were

observed in the thinner sectors. The risk was also higher in obese patients and the risk decreased with more experienced surgeons. The trocar could reach the external iliac artery on pelvic CT scans in the four most anterior sectors with a higher frequency in women. Posterior sectors were at risk for sciatic nerve and gluteal vessel damage when the trocar was pushed deeper than 6 cm into the posterior iliac crest. In cadavers, the dissection demonstrated nine vascular or neurological lesions. **Conclusions** Using the sector system, trocars can be directed away from neural and vascular structures and toward zones that are likely to contain larger bone marrow stock.

**Keywords** Bone marrow aspiration · Complications  
Sector rule for marrow aspiration · Ilium anatomy ·  
Iliac crest anatomy · Iliac artery · Neurologic complication

## Introduction

There has been growing clinical interest in the harvesting of autologous mesenchymal stem cells [5] through bone marrow aspiration from the iliac crest. Autologous bone grafts [2, 6] are used in orthopaedic, neurosurgical and maxillofacial surgeries, but there is a risk of pain and morbidity at the donor site. Therapies based on autologous bone marrow cells [8–11] have been examined as a treatment for delayed union or nonunion, malunion, arthrodesis, limb salvage and reconstruction of bone defects [13]. Autologous cells harvested from the iliac crest bone marrow can be used as other alternative therapies [7] without the complications compared to standard bone grafts.

Little information [14] documenting the risks of bone marrow aspiration in the iliac crest in orthopaedic surgery is present in the literature. Little attention has been paid to the risk to anatomical structures when the aspiration trocar (which is 10 cm long) penetrates the cortex of the iliac bone but fails to remain within the tables of the crest. Typically, advancing

J. Hernigou · L. Picard · A. Alves · P. Hernigou (✉)  
Department of Orthopedic Surgery, Hôpital Henri Mondor, Créteil,  
France  
e-mail: philippe.hernigou@wanadoo.fr

J. Silvera  
Radiology Department, Hôpital Européen Georges Pompidou,  
Créteil, France

Y. Homma  
Orthopaedic Surgery Department, Juntendo University, Bunkyo,  
Japan

the trocar by hand often requires excessive downward force and should the needle suddenly lose contact with bone, perforation of the abdominal cavity and potential visceral injury may result as it has been reported [3, 4, 16, 18] in the haematological literature. Although orthopaedic surgeons are very familiar with the structures that are anterior, superior and posterior to the iliac crest, many are not as well acquainted with those that lie medial or inferior to it, and there is a need to understand the risks due to bony, vascular and neurological anatomy of the iliac crest and the pelvis. Our interest was piqued after performing bone marrow aspiration [12] in 1,800 patients treated between 1990 and 2011 at the Department of Orthopedic Surgery, Henri Mondor Hospital (Paris, France) where we observed major haematoma (four cases needing transfusion), sciatic palsy (one transient case) and three transient episodes of numbing in the area of the lateral femoral cutaneous nerve occurring after bone marrow aspiration. Although the risk of complication of bone marrow aspiration [14] is lower than the risk of conventional harvesting of pieces of the iliac bone [15, 17], and although these patients did not need vascular surgery, their cases prompted us to determine the danger of inadvertent impingement by a trocar introduced into the iliac crest on the structures that lie adjacent to the iliac bone.

Our hypothesis was that when the trocar is introduced into some areas of the iliac crest there is a higher risk of incorrect angle or excessively deep penetration, particularly in zones where the iliac bone is thin. This is due to potentially thinner bone width in some parts of the iliac bone and the need for placing the trocar in the ilium wing bone between the two tables when entering the iliac crest. Our secondary hypothesis was that there would be an increased risk of injury to vascular structures in specific intrapelvic and extrapelvic anatomical structures during implantation of the trocar.

Therefore, we have chosen to divide the iliac crest into six different zones of the iliac crest known as sectors. The sectors were imaged on a series of injected pelvic computed tomography (CT) scans that measured the thickness, maximum available bone depth for trocar purchase in these different parts of the iliac crest and the corresponding vascular structures at risk. Two series of patients were followed: (1) patients who had measurements of distance and angles of the structures at risk with the ilium and (2) patients who had bone marrow aspiration with an evaluation of the risk of a trocar being directed outside the iliac wing.

## Materials and methods

Three different types of patient positioning and three different approaches can be used to harvest bone marrow from the iliac crest: patient supine and anterior crest approach, patient prone and posterior iliac crest approach and patient in the left or right lateral position allowing medial iliac crest approach. The needle should be inserted between the outer and inner tables

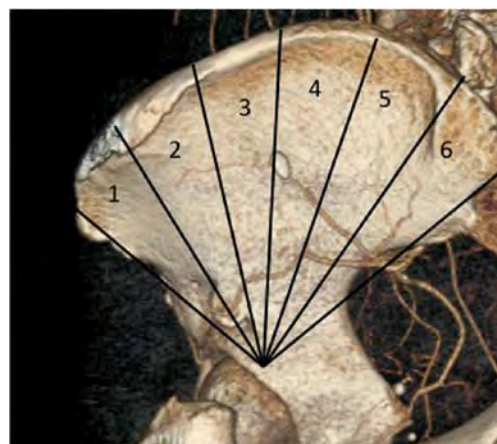
of the iliac bone. When the patient is thin enough for the ilium to be grasped between the thumb and finger of the left hand, a direct approach is possible and straightforward. When the patient is heavier, it is more difficult to retract any overhanging skin and subcutaneous fat and grasp the iliac crest between the thumb and fingers. In this situation, the needle tip is used to “palpate” the iliac crest and, once the centre of the crest is located, the needle tip is seated into the cortical bone with one or two brisk taps with a small, lightweight mallet. However, advancing the needle by hand or with a mallet often requires excessive downward force and should the needle suddenly lose contact with bone, this may result in the needle perforating the abdominal cavity with the potential for visceral injury.

## Definition of the different sectors

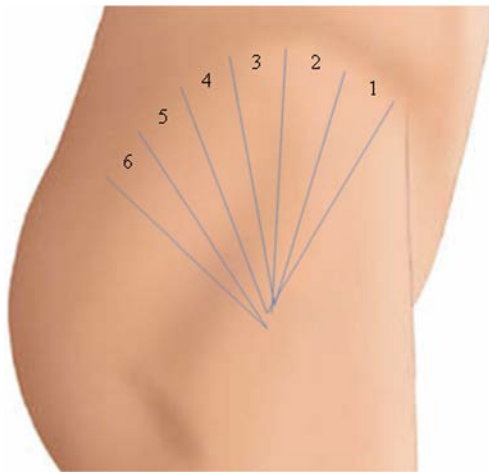
The iliac wing sectors were formed by extending lines from the anterior superior and posterior superior iliac spine through the centre of the acetabulum and the bisecting line of the angle formed by the two previous lines, resulting in anterior and posterior halves (Fig. 1). The mean length of the iliac crest is 24 cm, and each half of the iliac wing was divided into three sectors by drawing lines from points 4 cm apart on the iliac crest to the centre of the hip. These lines were approximately perpendicular to the curve of the iliac crest. The six sectors were defined by these lines (Fig. 1). The corresponding sectors can be found and marked on the patient by using the same technique (Fig. 2).

## Assessing the risk by sector for adverse placement of the trocar

To assess the risk by sector of a trocar being outside the iliac crest during bone marrow aspiration, the authors examined six



**Fig. 1** The iliac wing (three-dimensional reconstruction) was divided by drawing lines from equidistant points spaced along the rim of the iliac crest to the centre of the hip. These lines were approximately perpendicular to the curve of the iliac crest. Six sectors were defined by these lines. Sectors 1 and 2 anterior part of the iliac bone, sectors 3 and 4 centre part of the iliac bone, sectors 5 and 6 posterior part of the iliac bone



**Fig. 2** The corresponding sectors can be found and marked on the patient by using the same technique and correspond in clinical practice to different zones of bone marrow aspiration according to the position of the patient. Three different approaches can be used to harvest bone marrow from the iliac crest: patient supine and anterior crest approach (sectors 1, 2 and 3), patient prone and posterior iliac crest approach (sectors 4, 5 and 6) and patient in the left or right lateral position allowing easier middle iliac crest approach (sectors 3 and 4)

surgeons performing different entry points in 120 patients. The number of times there was a risk of the needle losing contact with bone was determined on a series of 40 patients for each type of position (supine, prone or lateral). Each patient received four entry points on two adjacent sectors (e.g. two in sector 1 and two in sector 2), corresponding to a total of 480 entry points. The trocar was 10 cm long and 8 gauge diameter. These patients (55 men and 65 women) averaged 43 years of age (range 18–68 years). Patients were divided into two groups according to their body mass index (84 patients with BMI <30 and 36 obese patients with BMI >30). Surgeons were divided into two categories according to their experience: three surgeons who had done fewer than ten bone marrow harvesting procedures at the start of the study period and three surgeons who had done more than 50 procedures. The angle between the correct position and the wrong direction (i.e. the

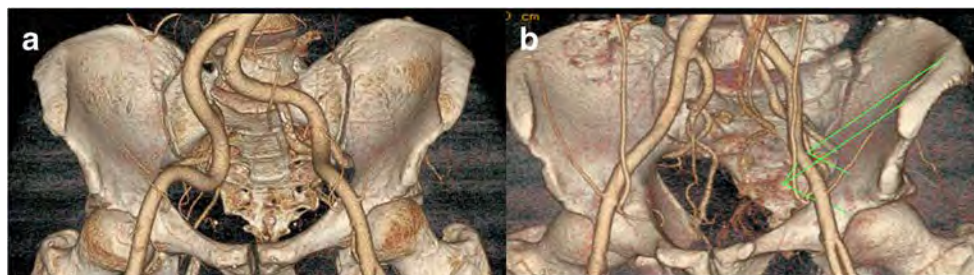needle losing contact with bone) of the trocar was measured and it was never found to be higher than 20°.

#### Anatomical structures potentially at risk by sector

To describe the anatomical structures that are at risk during trocar placement, we determined the relative contiguity of intrapelvic neural and vascular structures to trocars inserted into specific sectors of the iliac bone. Measurements were done on injected CT scan (Fig. 3) of 24 anonymous pelvic angio-CT scans of mature adults. The CT scans were performed for the vascular exploration of 12 men and 12 women. The patients had a median age of 50 years (range 24–91 years). From the two-dimensional transversal images with 1-mm cuts (Fig. 3), three-dimensional reconstructions (Fig. 3) were made using software (LightSpeed, General Electric). Measurements were performed on the CT scans of the 24 normal pelvises (48 hemi-pelvises). The scans were examined from the level of the anterior iliac crest anteriorly to the level of the posterior iliac crest and the sciatic notch posteriorly, from the iliac crest proximally to the acetabulum distally and the ischial spine posteriorly. The sectors were defined as previously described on the three-dimensional reconstructions. The transverse distance (T) of the external iliac artery from the inner pelvic table (Fig. 4a, b), the distance (D) between the iliac crest and external iliac artery and the angle (A) between the iliac wing direction and the line joining the external iliac artery to the iliac crest were measured on the 24 radial CT scan cuts of each of 48 hemi-pelvises of these patients (1,152 cuts) and results reported as the mean for each sector.

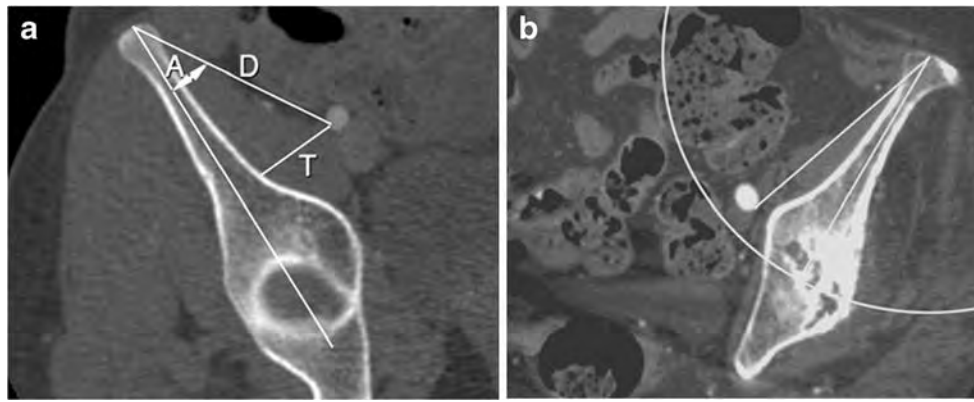
#### Distances between vascular structures and bone

Observation of the radio-enhanced vasculature on the scans made it possible to determine the anatomical course and proximity of these vessels to a virtual trocar placed through the iliac crest. Because the angle between the correct position (plane of the iliac wing) and the wrong direction (the needle losing contact with bone) during the insertion of a trocar was never



**Fig. 3** From the two-dimensional transversal images with 0.6-mm cuts, three-dimensional reconstructions were made using software (LightSpeed, General Electric). Measurements were performed on the CT scans of the 24 normal pelvises (48 hemi-pelvises). **a** The relative contiguity of intrapelvic neural and vascular structures to trocars inserted into specific sectors of the iliac bone was analysed. **b** An anatomical

structure was considered to be at risk if the structure was situated in the corresponding volume delimited by these conditions (e.g. iliac wing of the sector, angle of 20° and height of 10 cm). Consequently, the pelvis was divided into six volumes at risk corresponding to each sector of the iliac crest. The limits of the volume corresponding to sector 1 are represented in green



**Fig. 4** Of each of the 48 hemi-pelves, 24 radial CT scan cuts were analysed. **a** The transverse distance ( $T$ ) of the external iliac artery from the inner pelvic table, the distance ( $D$ ) between the iliac crest and external iliac artery and the angle ( $A$ ) between the iliac wing direction and the line joining the external iliac artery to the iliac crest were measured on the 24

radial CT scan cuts of each of the 48 hemi-pelves of these patients (1,152 cuts) and results reported as the mean for each sector. **b** In this example, the angle between bone and artery is  $18^\circ$ ; the distance from the iliac crest to the vessel is less than 10 cm (*circle*), so the artery is in the sector at risk

found to be greater than  $20^\circ$  (with residents or surgeons), an anatomical structure was considered to be potentially at risk in a sector if it was accessible to the tip of the trocar (length 10 cm) introduced into the iliac crest with a deviation of  $20^\circ$  from the plane of the iliac wing. In other words, an anatomical structure was considered to be at risk if the structure was situated in the corresponding volume delimited by these conditions (e.g. iliac wing of the sector, angle of  $20^\circ$  and height of 10 cm). Consequently, the pelvis was divided into six volumes at risk corresponding to each sector of the iliac crest. The limits of the volume corresponding to sector 1 are represented in green.

#### *Risk for a trocar to reach the sciatic nerve and gluteal vessel*

The shortest distance from the posterior superior iliac spine or the iliac crest to the sciatic notch on a CT scan image was measured. This distance was used as an evaluation for the shortest distance from the iliac crest to the superior gluteal vessel and sciatic nerve when these structures were not visualised on the CT scan. When they were correctly identified on a CT scan, the same procedure as described for the external iliac artery was used to determine the risk level.

#### *Thickness of the iliac crest*

The thickness of the iliac crest (transverse thickness between the two tables) is one of the most important factors in ensuring the safe placement of the trocar between the two tables of the iliac wing. Multiple CT scan images were reconstructed perpendicular to the iliac crest and directed to the centre of the hip to obtain radial cuts (Fig. 4) concentric with the hip centre (two radial cuts for each sector, average  $10^\circ$  of angulation between two consecutive cuts). On each image (named radial cut), the thickness of the iliac crest was measured at different depths for each centimetre of the iliac wing from the superficial iliac crest to the maximum depth allowed by the trocar.

#### Statistical analysis

Statistical analysis was performed using “logiciel excel” for Windows. Descriptive statistics were obtained on all variables collected during the study. The continuous variables included angle, distance from trocar to vital structures, distance from pelvic bone to structure and bone thickness in each of the zones studied. Categorical values were side, age, sex, height size, BMI and sector. A  $p$  value less than 0.05 was considered significant. Inter-observer reliability was assessed by calculating the intraclass correlation coefficient (ICC) for repeated measurements.

#### Results

##### Variations of the thickness of the ilium in the different sectors

For sector 1 (Table 1), the mean bone thickness was 3.4 mm. In sector 2, the mean bone thickness was 4.6 mm. This implies

**Table 1** Average thicknesses of the spongy iliac bone

		Mean thicknesses (cm)	Standard deviation	Min.–max.
Anterior zone	Sector 1	0.8	0.3	0–1.5
	Sector 2	1.3	0.4	0.5–2.5
Medial zone	Sector 3	1.7	0.4	0.3–3.5
	Sector 4	1.4	0.6	0–3.6
Posterior zone	Sector 5	1.2	0.5	0–3.7
	Sector 6	2.1	0.2	0.9–3.2

The mean, standard deviation and range for the 36 points measured in each sector are indicated. On each sector the thickness of the spongy bone was measured on 4 radial cuts; on each radial cut the thickness was measured every centimetre at a depth of 9 cm from the iliac crest (measurement on 36 points for each sector)

that the more anterior the trocar is placed in the iliac crest, the worse the bone stock will be. In contrast, the greatest bone thickness was found in sectors 5 and 6, which had a mean thickness of 4.9 and 9.6 mm, respectively. When compared with the average bone mass of the anterior, it was evident that the more posterior iliac crest had greater bone thickness. This was true for the entire posterior. The bone thickness in sector 4 averaged 3.5 mm. This area is the thinnest part of the iliac crest. There was no correlation between the thickness of the iliac crest and sex, age, side (left or right), height and BMI ( $p>0.05$  for all).

#### Breaching risks of the medial or lateral table during bone marrow aspiration

Among the 480 entry points, 94 breaches were observed. During insertion of the trocars, entering the inside table was more frequent (62 breaches). The major factors that increased the risk of damage were the sector zone, inexperience of the surgeon and obesity of the patient. Higher numbers ( $p=0.02$ ) of breaches were observed in sector 4 (38/94 events, 40 %), sector 1 (26/94 events, 31 %) and sector 5 (24/94 events, 25 %). The remaining ten breaches occurred in sector 2 (four events), sector 3 (two events) and sector 6 (four events). The number of breaches was higher (75 among 240 entry points, 31 %) for surgeons with fewer than ten bone marrow harvests compared to a lower number of breaches (19 among 240 entry

points, 8 %) observed with surgeons with more than 50 bone marrow harvests prior to participation in the study. When the patient was obese (BMI >30), the risk increased (69 breaches of 240 entry points, 29 %). Sex and age of the patients had no influence on the risk ( $p<0.05$ ). Among the 40 patients with two entry points in sector 1, one patient had a transient numbness in the area of the lateral femoral cutaneous nerve, and two patients had haematoma.

During normal insertion of the trocars, entering the inside table is more frequent due to the shape of the iliac crest. The major factors that increased the risk of damage were the sector zone, the inexperience of the surgeon and obesity of the patient. The angle between the ideal position and the incorrect position was measured for each time when the trocar lost contact with bone. The maximum deviation was 20° with an average of 8°. Surgical experience was the most important factor in ensuring safe placement of the trocar between the two tables of the iliac wing.

#### Vascular and neurological structures at risk on angio-CT scan

##### *Risk for the trocar to reach the external iliac artery*

Measurements of distances D and T, and values of angle A, are indicated in Table 2. When a deviation of the trocar of 20° from the plane of the iliac wing resulted from technical error, there was a risk of the trocar (with a length of 10 cm) reaching

**Table 2** The distances T and D, and the angle A, varied widely in the different sectors. No correlation was found between these values and patient height and BMI. We observed no differences ( $p>0.05$ ) in these values between the right and left sides. However, we found that the distance T and the angle A were significantly ( $p<0.05$ ) decreased in women as compared with men and in older patients (50 years) compared with younger patients in each sector. The large variation of distance T and angle A could be due to different volumes of psoas muscle interposed between the bone and the external iliac artery

	Sector 1	Sector 2	Sector 3	Sector 4
Distances (T) between Iliac bone and external Iliac artery (mm)				
Mean, mm (min.–max.)	23.6 (6.7–40.9)	24.4 (5.3–40.8)	29.3 (4.7–54.9)	43.3 (3.2–75.7)
Mean, age <50 years	25.63	28.92	36.04	49.93
Mean, age >50 years	21.60	19.96	22.59	36.58
Student's <i>t</i> test, <i>p</i>	0.021	<0.001	<0.001	0.01
Mean, women	20.77	21.65	25.54	41.50
Mean, men	26.46	27.23	33.09	45.01
Student's <i>t</i> test, <i>p</i>	0.001	0.01	0.01	0.53
Mean, height <1.7 m	22.16	22.45	25.71	37.17
Mean, height >1.7 m	25.33	26.80	33.57	50.44
Student's <i>t</i> test, <i>p</i>	0.06	0.02	0.003	0.03
Distances (D) between the iliac crest and the external Iliac artery (mm)				
Mean (min.–max.)	68.7 (29.6–89.6)	89.4 (66.4–111.2)	99.8 (70.6–129.5)	95.8 (0–125.8)
Mean, age <50 years	64.03	84.55	95.95	94.14
Mean, age >50 years	73.41	94.17	103.72	97.46
Student's <i>t</i> test, <i>p</i>	0.009	<0.001	0.02	0.63
Angle (A) between the iliac wing direction and the line joining the external iliac artery to the iliac crest				
Mean (min.–max.)	20.5 (4.5–41.3)	16.4 (3.2–31.9)	17.5 (2.7–35.5)	26.3 (0–48.9)
Mean, age <50 years	23.5	20.3	22.2	32.6
Mean, age >50 years	17.6	12.4	12.8	22.3
Student's <i>t</i> test, <i>p</i>	0.003	<0.001	<0.001	<0.001

the iliac artery in sectors 1, 2 and 3 (Table 3). The frequency was higher in sectors 1 and 2. The average distance T (Table 2) was observed to be 23.6 mm (range 6.7–41 mm) on the CT scan. The average distance D between the iliac crest and the external iliac artery was observed to be 69 mm (29–89 mm) in sector 1 (Table 2) on the radial CT scan image. The average angle A (Table 4) was observed to be 20.5° in sector 1. The distances T and D, and the angle A, varied widely in the different sectors. No correlation was found between these values and patient height and BMI. We observed no differences ( $p>0.05$ ) in these values between the right and left sides. However, we found that the distance T and the angle A were significantly ( $p<0.05$ ) increased in women as compared with men and in older patients (>50 years) compared with younger patients in each sector. The large variation of distance T and angle A could be due to different volumes of psoas muscle interposed between the bone and the external iliac artery (Fig. 3). For sector 4 the iliac wing is thin (Table 1), which theoretically increases the probability for the trocar to go outside the bone with a risk of vascular injury. However, when a trocar is inserted into sector 4, the trocar most often lies within the psoas muscle when the angle A of deviation is less than 20°. Due to variations in the distance T and angle A, the artery in sector 4 was at risk at a higher frequency in women (Table 3). This probably is due to the thinner psoas muscle in women as compared with men. In women older than 50 years, this frequency is increased for the same reasons.

#### *Risk for the trocar to reach the sciatic nerve and gluteal vessel*

Trocars placed in posterior sectors may be directed toward the sciatic nerve and the superior gluteus artery, but remain distant to the external iliac vessels. The average distance between the iliac crest and the notch is 70 mm (minimum 56.6 mm) in sectors 5 and 6 (Table 4). This distance is decreased in women and small people, but is increased in heavy people. Therefore, a trocar inserted from the posterior part of the iliac crest and introduced deeper than 60 mm (with a deviation of only 5° from the plane of the iliac wing) may reach the sciatic nerve and superior gluteal vessel. At the level of the sciatic notch, the distance from the bone averaged only 8 mm (range 5–10 mm). After exit from the pelvis, at 1 cm from the sciatic

**Table 3** Number and frequency (%) of artery being situated in the volume (prism) delimited on 48 hemi-pelves with the following landmarks: iliac wing of the sector, angle of 20° and height of 10 cm

	Sector 1	Sector 2	Sector 3	Sector 4
Women ( $n=24$ )	16 (67 %)	21 (87.5 %)	8 (33 %)	7 (29 %)
Men ( $n=24$ )	6 (25 %)	9 (37.5 %)	1 (4 %)	0 (0 %)
$p$	<0.005	<0.001	<0.03	<0.02
Test	$\chi^2$	$\chi^2$	Yates	Yates

**Table 4** Average distances between the posterior iliac crest and the sciatic notch

Mean (min.–max.)	70.3 (56.6–84.3)
Women	66.7
Men	73.9
Student's $t$ test, $p$	<0.001
Mean, height <1.7 m	66.2
Mean, height >1.7 m	74.4
Student's $t$ test, $p$	<0.001
Mean, weight <79 kg	67.7
Mean, weight >79 kg	72.9
Student's $t$ test, $p$	<0.006

notch the sciatic nerve was an average distance of 12 mm (range 8–20 mm) from the bone. At the ischial spine, the distance between the sciatic nerve and the iliac crest increased to 15 mm (range 13–22 mm) due to the presence of muscle tissue (gemelli, obturator internus and quadratus femoris muscles). The superior gluteal vessels were closest to the pelvic bone at the superior portion of the sciatic notch. CT scans of the pelvis (opacified vascular) at this level showed that the superior gluteal vessels were an average distance of 5 mm (range 2–10 mm) from the greater sciatic notch.

## Discussion

Percutaneous bone marrow aspiration clearly has fewer complications than bone graft harvesting. However, the risk is not zero and complications have been reported [3, 4]. Amann et al. [1] reported a case of intestinal puncture requiring operative repair during bone marrow harvest. We have observed the development of haematomas that required transfusion. The complexity of the anatomy of the pelvis cannot prevent all morbidity even when using a needle. Even when the safe zones for the placement of the trocar are known, the structures can be damaged by inadvertent violation of the intrapelvic region. Information about the effect of the position of the vascular and neurological anatomy in relation to the iliac crest may be helpful in avoiding iatrogenic vessel injury. Understanding how anatomical position differs between sectors can inform surgeons about the anatomical structures that are at risk.

We performed a study with two series of patients in which measurements of distance and angle of structures of the iliac were measures in one study, and in the other study the risk of a trocar being directed outside of the iliac wing during bone marrow aspiration was determined. While the incidence of injury to major vascular structures during bone marrow aspiration is low, the importance of this topic is reflected by the

inordinately high associated morbidity and mortality, which may affect patients with vascular injuries.

Although an appreciation of the anatomy of the pelvis cannot prevent all morbidity, it is possible that injuries to neurological or vascular structures in the pelvis can be avoided with knowledge of several simple pelvic dimensions. The anatomical structures that are contiguous to the iliac bone, which are not visible to the surgeon during bone marrow aspiration, have been illustrated in many anatomical publications. These structures are the external iliac, superior gluteal arteries and the sciatic nerve. To minimise risk during placement of the trocar, it is necessary to define the relationship of these neural and vascular structures to the osseous iliac crest, which is the only structure that the surgeon is able to identify by palpation. This study was performed in order to define the anatomical structures that are at risk during trocar placement, to determine the relative contiguity of intrapelvic neural and vascular structures to trocars placed in specific locations of the iliac crest, to develop a sector system to guide placement of the trocar and to highlight the risks associated with each sector zone.

We based our measurements on several factors. In determining the distance to the sciatic notch and arteries, studies in the past have used cadaveric measurements to determine the approximate location of the gluteal vessels and nerves. It was our intent to give the surgeon an indication of the shortest distance to the notch and, therefore, the safest bony measurement in living patients since the muscles and the arteries may have different positions as seen in cadaveric tissue, so we used measurements on CT scans of patients.

This study has several limitations. There was variability of specimen size and shape that we could not control. Despite this, our standard deviations were relatively small and the relative behaviour of the ilium was fairly consistent. Furthermore, CT scanograms were obtained in patients without general anaesthesia, so there could be a reduction in the results recorded for the distance T and angle A in patients with anaesthesia, since the psoas muscle will be less contracted in anaesthetised patients. Risk factors for vascular injury also include pre-existing surgery in the area of the abdomen or vessels, retroperitoneal inflammatory process and vascular disease that were not examined here.

The sector system that we have developed for locating the position of neural and vascular structures that are at risk during bone marrow aspiration is easy to construct. For simplicity, lines drawn between the anterior and posterior superior iliac spines that divide the iliac crest into six equal sectors can be used to form the sectors. The sectors can be used to locate safe and dangerous zones for the placement of trocars. To minimise the risk of vessel injury, meticulous surgical technique and limited depth of instrument placement are essential. Surgical risk is greatest when the iliac wing is thin and when a structure is contiguous to the surface of the intrapelvic bone

(with little interposition of tissue or iliac bone) and/or is relatively adherent to the pelvis. Trocar placement in the second anterior sector represents a commonly used position for a patient in a supine position. If placed in the most posterior superior sector, the trocar may be directed toward the sciatic nerve and the superior gluteal nerve and vessels. In contrast to the shallow bone in the anterior sectors, the bone width in the posterior sectors 5 and 6 allows trocars to be placed easily in the posterior iliac crest.

In conclusion, the sector system was found to be helpful during bone marrow aspiration. Trocars can be directed away from neural and vascular structures and toward zones that are likely to contain the best available bone marrow stock. It could be recommended that instruments be marked with distances from the instrument tip so that depth of penetration can easily be appreciated during bone marrow aspiration. Such a recommendation should, however, be used with caution to avoid a false sense of security since the angle and the orientation of a trocar insertion also impacts the risk of injury.

**Acknowledgements** We thank Ted Sand and Richard Suzuki and the other members of Celling Biosciences for the review of the final manuscript, and their help in translation.

## References

- Amann B, Luedemann C, Ratei R, Schmidt-Lucke JA (2009) Autologous bone marrow cell transplantation increases leg perfusion and reduces amputations in patients with advanced critical limb ischemia due to peripheral artery disease. *Cell Transplant* 18(3): 371–380
- Arrington ED, Smith WJ, Chambers HG, Bucknell AL, Davino NA (1996) Complications of iliac crest bone graft harvesting. *Clin Orthop Relat Res* 329:300–309
- Bain BJ (2005) Bone marrow biopsy morbidity: review of 2003. *J Clin Pathol* 58(4):406–408
- Ben-Chetrit E, Fusser D, Assaf Y (1984) Severe bleeding complicating percutaneous bone marrow biopsy. *Arch Intern Med* 144:2284
- Chevallier N, Anagnostou F, Zilber S, Bodivit G, Maurin S, Barrault A, Bierling P, Hernigou P, Layrolle P, Rouard H (2010) Osteoblastic differentiation of human mesenchymal stem cells with platelet lysate. *Biomaterials* 31(2):270–278
- Cockin J (1971) Autologous bone grafting—complications at the donor site. *J Bone Joint Surg Br* 53:153
- Dahabreh Z, Calori GM, Kanakaris NK, Nikolaou VS, Giannoudis PV (2009) A cost analysis of treatment of tibial fracture nonunion by bone grafting or bone morphogenetic protein-7. *Int Orthop* 33(5):1407–1414
- Hernigou P, Beaujean F (2002) Treatment of osteonecrosis with autologous bone marrow grafting. *Clin Orthop Relat Res* 405:14–23
- Hernigou P, Poignard A, Beaujean F, Rouard H (2005) Percutaneous autologous bone-marrow grafting for nonunions. Influence of the number and concentration of progenitor cells. *J Bone Joint Surg Am* 87:1430–1437
- Hernigou P, Poignard A, Manicom O, Mathieu G, Rouard H (2005) The use of percutaneous autologous bone marrow transplantation in nonunion and avascular necrosis of bone. *J Bone Joint Surg Br* 87(7): 896–902
- Hernigou P, Mathieu G, Poignard A, Manicom O, Beaujean F, Rouard H (2006) Percutaneous autologous bone-marrow grafting

- for nonunions. Surgical technique. *J Bone Joint Surg Am* 88(Suppl 1 Pt 2):322–327
12. Hernigou P, Homma Y, Flouzat-Lachaniette CH, Poignard A, Chevallier N, Rouard H (2013) Cancer risk is not increased in patients treated for orthopaedic diseases with autologous bone marrow cell concentrate. *J Bone Joint Surg Am* 95(24):2215–2221
  13. Hernigou P, Pariat J, Queinnec S, Homma Y, Lachaniette CH, Chevallier N, Rouard H (2014) Supercharging irradiated allografts with mesenchymal stem cells improves acetabular bone grafting in revision arthroplasty. *Int Orthop*. doi:10.1007/s00264-014-2285-2, PMID: 24509980
  14. Hernigou P, Desroches A, Queinnec S, Flouzat Lachaniette CH, Poignard A, Allain J, Chevallier N, Rouard H (2014) Morbidity of graft harvesting versus bone marrow aspiration in cell regenerative therapy. *Int Orthop*. doi:10.1007/s00264-014-2318-x
  15. Kahn B (1979) Superior gluteal artery laceration, a complication of iliac crest bone graft surgery. *Clin Orthop* 140:204–207
  16. Pedersen LM, Jarner D, Winge J (1993) Bone-marrow biopsy of the iliac bone followed by severe retroperitoneal hemorrhage. *Eur J Haematol* 51:52
  17. Schizas C, Triantafyllopoulos D, Kosmopoulos V, Stafylas K (2009) Impact of iliac crest bone graft harvesting on fusion rates and post-operative pain during instrumented posterolateral lumbar fusion. *Int Orthop* 33(1):187–189
  18. Tsai HL, Liu SW, How CK et al (2008) A rare case of massive retroperitoneal hemorrhage after bone marrow aspiration alone. *Am J Emerg Med* 26(9):1070.e5–1070.e6